 [Print this Page for Your Records](#)

[Close Window](#)

Control/Tracking Number: 10-O-1479-ASNR

Activity: Scientific Paper (Oral Presentation)

Current Date/Time: 12/11/2009 7:16:40 PM

Maximum intensity 3D FLAIR reformations: increased white matter lesion conspicuity

Author Block: Hill, V. B.¹·Weiss, K. L.¹·Lin, Y.¹·Hebert, K. J.¹·Thangasamy, S. J.¹·Ying, J.¹·Weiss, J. L.²·Melanson, M. J.¹

¹University of Cincinnati, Cincinnati, OH, ²WestImage, Cincinnati, OH.

Abstract:

Purpose: Maximum intensity projections have been used to great advantage in MRI, most notably MR angiography. Our study was performed to determine whether maximum intensity axial reformations derived from sagittal 3D fluid-attenuated inversion-recovery (FLAIR) source images increase the conspicuity of white matter lesions.

Materials & Methods: Multisequence brain MRI, including 4mm interleaved axial FSE T2 and FLAIR; and sagittal 3D FLAIR (TR/TE 6000/127, ETL 160; 1.6 mm section thickness/-0.8 spacing, fat-saturation) with maximum and average intensity axial reformations was performed on a 3.0T GE MRI scanner (GE, Waukesha, WI). Three neuroradiology fellows compared the conspicuity of white matter lesions on axial T2-FSE, T2 FLAIR, and corresponding 3D reformations. A Poisson model was used to assess the association of conspicuity to the fixed effect of imaging methods, interacting with disease types and adjusting for raters. Means of counts were compared between maximum intensity reformats and other methods under the Poisson model framework and adjusted for multiple comparison using a Bonferroni's method. Inter-rater reliability of measure was assessed

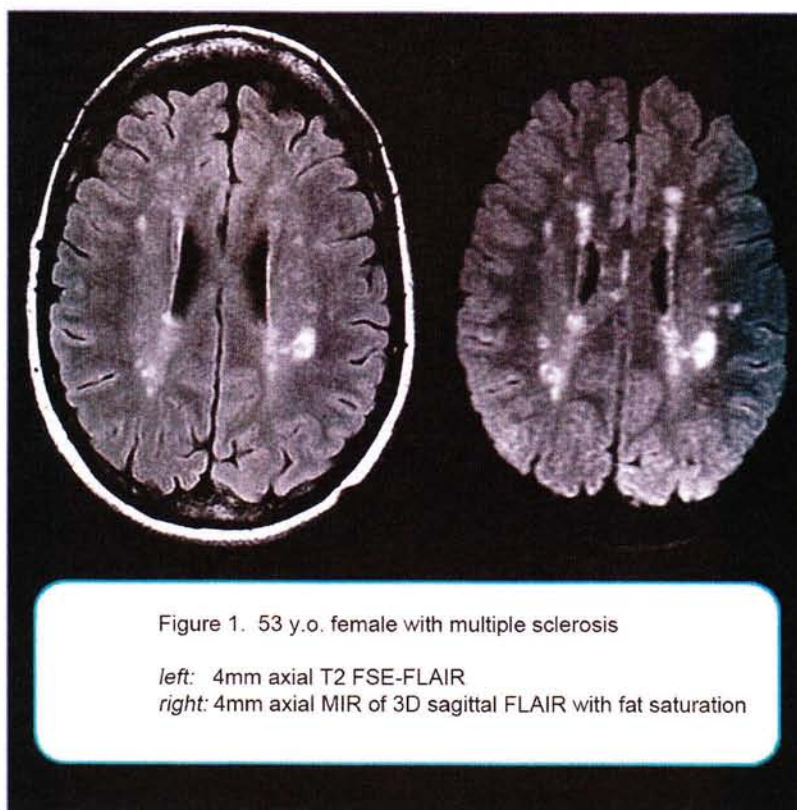


Figure 1. 53 y.o. female with multiple sclerosis
 left: 4mm axial T2 FSE-FLAIR
 right: 4mm axial MIR of 3D sagittal FLAIR with fat saturation

using an intra class correlation (ICC).

Results: Thirty-three patients were studied. Twenty-four patients had multiple sclerosis (MS) (19-62 years old; 19 women, five men), six had hearing loss and/or vertigo (34-71 years; four women, two men), and three had sarcoidosis (50-56 years; all women). The mean (95% confidence interval or CI) of conspicuous image slices was 8.68 (6.61, 11.41) using maximum intensity reformats, higher than those of 2.08 (1.47, 2.94), 3.21 (2.31, 4.48), and 1.09 (0.71, 1.68) using FLAIR, average intensity reformats and T2 respectively (p-values<0.05). Maximum intensity reformats also showed more conspicuous image slices in MS, hearing loss/vertigo (IAC) and sarcoid patients respectively. The inter-rater reliability was good with an ICC of 0.60.

Table1. Summary of conspicuity measures

		Count of conspicuous imaging slices	Count of conspicuous imaging slices above AC	Count of conspicuous imaging slices below AC
Patient type	Method	Mean (95% CI)	Mean (95% CI)	Mean (95% CI)
All n=33	MIR	8.68 (6.61, 11.41)	7.60 (5.87, 9.84)	1.38 (1.04, 1.85)
	FLAIR	2.08 (1.47, 2.94)*	1.90 (1.31, 2.76)*	0.23 (0.11, 0.47)*
	AIR	3.21 (2.31, 4.48)*	2.91 (2.11, 4.01)*	0.55 (0.34, 0.87)*
	T2	1.09 (0.71, 1.68)*	0.89 (0.59, 1.35)*	0.46 (0.28, 0.77)*

"**" indicates the mean is significantly different from that of the Maximum Intensity Reformat (MIR) with p<0.05.

Average Intensity Reformat = AIR.

Conclusion: White matter lesions are more conspicuous on maximum intensity reconstructions of 3D FLAIR data than they are on corresponding 2D FLAIR or T2-weighted images.

Author Disclosure Information: V.B. Hill, None; K.L. Weiss, None; Y. Lin, None; K.J. Hebert, None; S.J. Thangasamy, None; J. Ying, None; J.L. Weiss, None; M.J. Melanson, None.

Subject Category (Complete): ADULT BRAIN, New Techniques/Postprocessing ; ADULT BRAIN, Inflammatory/Infectious Diseases

Keyword (Complete): 3D MRI brain ; Maximum intensity projections MIP ; Multiple Sclerosis

Presentation Preference (Complete): Oral or Poster Presentation

Additional Information (Complete):

*Please type your full name in the text box: : Kenneth L. Weiss

*Please type in the date in the following format (MM/DD/YYYY): : 12/11/2009

*Has this work been previously published or presented?: No

*Will this work be published or presented in the future?: No

*Would you like to be considered for the Cornelius G. Dyke Memorial Award? (If NO, skip the following questions).: No

Off-Label Disclosure (Complete):

I have read the above statement and will conform to these requirements. : True

I have read the above statement. : True

The author/co-authors have off-label use to disclose. If yes, please provide the information requested below. It is required to disclose.: Yes

Product 1 : Investigational 3D FSE-XETA pulse sequences

Off-Label Use : MRI brain exams

Manufacturer : GE Healthcare

Status: Complete

[American Society of Neuroradiology](#)

2210 Midwest Road, Suite 207

Oak Brook, IL 60523-8205

Phone: (630) 574-0220

Fax: (630) 574-1740

TECHNICAL SUPPORT:

Phone: 217-398-1792 (Monday through Friday 9:00 am-5:00 pm Central Standard Time)

or Email: [OASIS Helpdesk](#)

Powered by [OASIS](#), The Online Abstract Submission and Invitation System SM

© 1996 - 2009 [Coe-Truman Technologies, Inc.](#) All rights reserved.